

Case Report

Presence of two Intussusceptions with Meckel's Diverticulum : A Case Report

Satyam Khare, Shilpi Jain, **Archana Sharma, *Nivesh Agarwal

Department of Anatomy, *Department of Surgery, Subharti Medical College, Delhi-Hardwar by pass road, Meerut-250002, **Department of Anatomy, Muzaffarnagar Medical College, Muzaffar Nagar-251001 (U.P.)

Abstract:

During the routine cadaveric dissection a Meckel's diverticulum was observed which was about 50 cms, proximal to the ileocaecal junction. The length of the diverticulum was about 7 cm. After exploring the abdomen we observed intussusceptions at two places; first intussusception was seen at about 30 cms from duodeno-jejunal junction & other one was 21 cm distal to the first one. Since presence of two intussusceptions along with Meckel's diverticulum is a rare and interesting finding, hence this case was considered suitable for discussion.

Key Words: Diverticulum, Intussusception, Intussusceptum, Intussusciens.

Introduction:

Although Meckel's diverticulum is one of the most prevalent congenital abnormality of the gastrointestinal tract, it is often difficult to diagnose (Turgeon & Barnett, 1990). It may remain completely asymptomatic, or it may mimic such disorders as Crohn's disease, appendicitis and peptic ulcer disease. Ectopic tissue found in approximately 50 percent of cases, consist of gastric tissue in 60 to 85 percent of cases and pancreatic tissue in 5 to 16 percent. (Elsayes et al, 2007). The diagnosis of Meckel's diverticulum should be considered in patients with unexplained abdominal pain, nausea and vomiting, or intestinal bleeding. Major complications include bleeding, obstruction, intussusceptions, diverticulitis and perforation.

Intussusception is a condition in which one part of the intestine slides into the next lower part. that is, there is a "telescoping" effect. This can lead to abdominal pain, obstruction, bleeding and potentially may compromise the blood supply to the bowel. Intussusception is one of the most common cause of intestinal obstruction in infants. It can occur at any age, but usually affects infants of 1 to 2 yrs. It happens much more often in boys than girls (Rabinowitz & Mills, 2008).

The word intussusception is derived from Latin word in which "intus" means-within and "suscipio"-to

take up. Invagination of the infolding of one segment of intestine within another; part within is called-intussusceptum, while part outside is called-intussusciens.

Brief Report:

During routine cadaver dissection of male cadaver aged about 55-60 years in Department of Anatomy, Subharti Institute of Medical Sciences, Meerut, a Meckel's diverticulum was seen about 50 cms proximal to ileocaecal junction. Subsequently after detailed examination two intussusception were seen. First one was present about 30 cms from duodenojejunal junction & second one was seen about 21 cms distal to the first one.

Gross examination: The Meckel's diverticulum was of about 7 cms in length (Fig. I). It

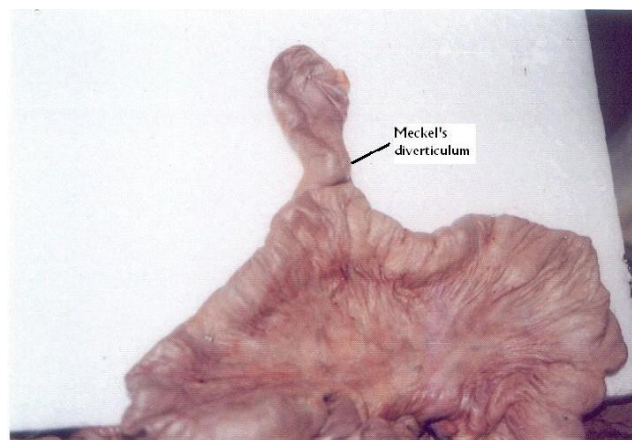


Fig. I: Photograph showing Meckel's diverticulum

Corresponding Author: Dr. Satyam Khare, Professor & HOD, Department of Anatomy, Subharti Medical College, Subhartipuram, Delhi Haridwar By Pass Road, Meerut – 250002 (U.P.)

Mob. No.: 0121-2534456, 09837083748

E-mail.: dr_kharsatyam@yahoo.com

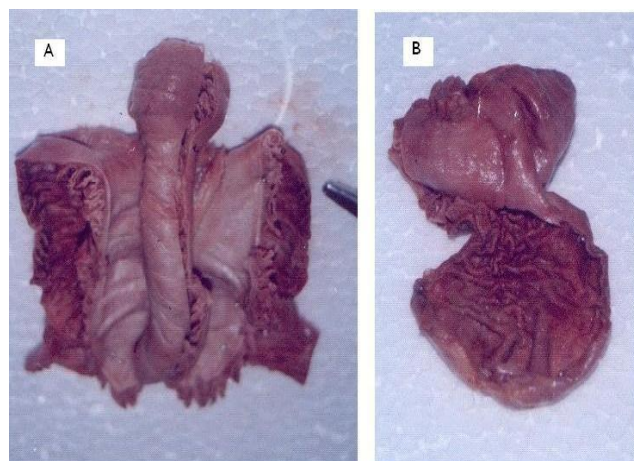


Fig. II: Photograph showing (a) Cut Intussusception
(b) Meckel's diverticulum (cut showing valves of Kerkrings)

appeared to be same as small intestine with slightly rounded apex. On cutting, it revealed valves of Kerkrings. (Fig. IIB).

Histological examination: Mucosa was flat and villi were not seen, lamina propria showed glands, congested capillaries & plasma cell infiltration. Submucosal region was oedematous. Muscular layer

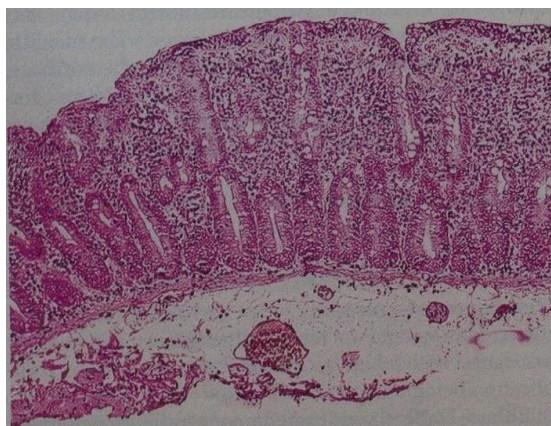


Fig. III: Photograph Showing Congested submucosa, with no villi.

showed inner circular and outer longitudinal layers with outermost serous coat (Fig.III).

Intussusception:

The first was seen 30 cms from duodenojejunal junction. Length was 9 cms and circumference of inner tube was 5.5 cms, middle tube 9.0 cms and outer tube 14 cms respectively (Fig. IV).

Second was seen 21 cms distal to first one. Length was 7 cms and circumference of inner tube was 4.5 cms, middle tube 7.5 cms and outer tube 10 cms respectively (Fig. V).

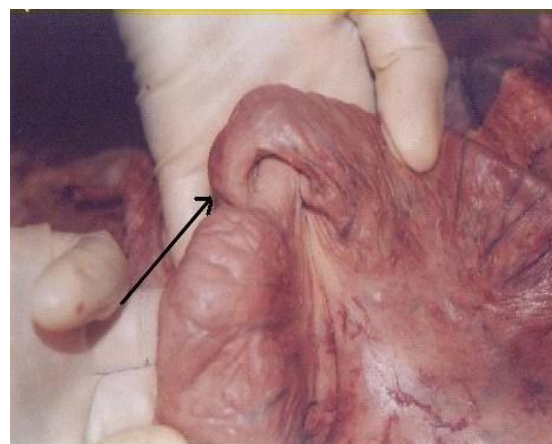


Fig. IV: Photograph showing proximal Intussusception (arrow).

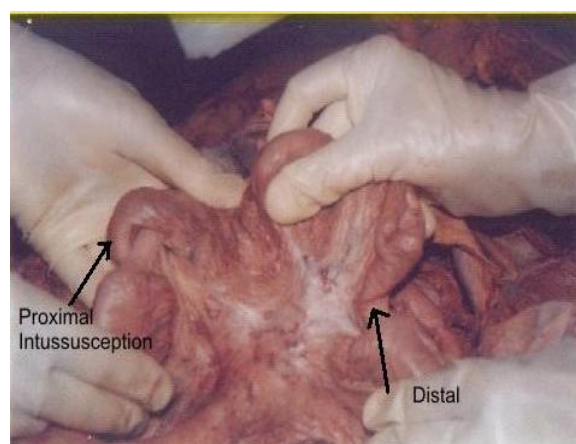


Fig. V: Photograph showing proximal and distal intussusception (arrow).

Except congestion no other apparent variation was seen from normal histology of small intestine.

Discussion:

The Meckel's diverticulum is a small out pouching, or *cul de sac* of tissue, protruding as a side passageway or side piece from the bowel lumen. The pouch is a remnant of tissue from the prenatal development of the digestive system. It is not made of the same type of tissue as the small intestine but instead is made of the type of tissue found in the stomach or the pancreas (Elsayes et al, 2007). Meckel's diverticulum is the most common birth defect of the digestive system. It is present in 15 to 30 out of every 1,000 live births. Most people with Meckel's diverticulum will never have any symptoms. One to three percent of all infants have symptoms of Meckel's diverticulum. The peak age for symptoms to occur is 2 years. Children

over 10 years rarely have symptoms of Meckel's diverticulum. Boys develop symptoms of Meckel's diverticulum three times more often than girls (Rabinowitz & Mills, 2008).

In most people, it is totally asymptomatic. Painless or painful rectal bleeding may occur. Obstruction of small intestine can also occur by two mechanisms. If the diverticulum becomes tangled in neighbouring loops of small intestine, it can cause a volvulus; or the diverticulum might invert, protruding into the ileal lumen, causing an intussusception. The Meckel's diverticulum might be discovered when a barium study or CAT scan of the small intestine is performed.

The confirmation of the Meckel's origin of the diverticulum rests on the visualization of its folds pattern, especially at the site of its attachments to the small bowel. A "triradiate" fold pattern in which the loops are collapsed and a "mucosal triangular plateau" in which the loops are distended are the junctional fold appearances that are considered characteristics. The incidence of Meckel's diverticulum in the general population has been estimated to be about 2 percent where as reports from autopsy and retrospective studies it range from 14 to 4.5 percent (Arnold & Pellicane, 1997; D' Souza et al, 1993). Although Meckel's diverticulum occurs equally in both sexes (Harkins, 1933), it causes complications more frequently in males and, therefore, is more often diagnosed in them (Leijonmarck et al, 1986). During early fetal development, the fetal midgut is attached to the yolk sac for nutrition via the omphalomesenteric duct/vitelline duct or yolk stalk (Arnold & Pellicane, 1997). If this duct does not involute by the seventh week of gestation, various developmental remnants may be left. Failure of the most proximal portion of the duct to obliterate results in a Meckel's diverticulum (Moore & Persaud, 1993; Moses, 1947).

The yolk sac is continuous with the embryo and contains all layers of the intestinal wall; therefore, the diverticulum that forms from the yolk stalk also contains all layers of the intestinal wall (Soltero & Bill, 1976). In addition to the normal layers of the intestinal wall approximately 50 percent of diverticula contain ectopic tissue (Artigas et al, 1986). Meckel's diverticulum arises from the anterior mesenteric border (that part of the intestine which lies opposite the mesenteric attachment). Ninety percent of the

diverticula are within 90 cm of the ileocecal valve, although diverticula up to 180 cm from the ileocecal valve have been observed. Its blood supply comes from a terminal branch of the superior mesenteric artery that crosses the ileum to the diverticulum. A person with Meckel's diverticulum has a 4 to 6 percent lifetime risk of developing a complication. The major complications are diverticulitis and perforation (Cullen et al, 1994; Leijonmarck et al, 1986; Mackey & Dineen, 1983; Williams, 1981). Bleeding is the most common complication of Meckel's diverticulum, but obstruction, intussusception, diverticulitis and perforation may also occur especially in adults. The presence of two intussusception in this case may be the complication of Meckel's diverticulum.

Bibliography:

1. Arnold JF, Pellicane JV: Meckel's diverticulum: A ten year experience. *The American Surgeon*, 1997;63(4):354-355.
2. Artigas V, Calabuing R, Badia F, Rius X, Allende L, Jover J: Meckel's diverticulum: value of ectopic tissue. *American Journal of Surgery*, 1986;151(5):631-634.
3. Cullen J, Kelly KA, Moir CR, Hodge DO, Zinsmeister AR, Melton LJ III: Surgical management of Meckel's diverticulum. An epidemiologic, population based study. *Annals of Surgery*, 1994;220(4):564-569.
4. D'Souza CR, Kilam S, Prokopishyn H: Axial volvulus of the small bowel caused by Meckel's diverticulum. *Surgery*, 1993;114(5):984-987
5. Elsayes KM, Menias CO, Harvin HJ, Francis IR: Imaging manifestation of Meckel's diverticulum. *American Journal of Roentgenology*, 2007;189(1):81-88.
6. Harkins HN: Intussusception due to invaginated Meckel's diverticulum- Report of two cases with a study of 160 cases collected from literature. *Annals of Surgery*, 1933;98(69):1070-1095,
7. Leijonmarck CE, Bonman-Sandelin K, Frisell J, Raf L: Meckel's diverticulum in the adult. *British Journal of Surgery*, 1986;73(2):146-149.
8. Mackey WC Dineen PA: Fifty year experience with Meckel's diverticulum. *Surgery, Gynecology & Obstetrics*, 1983;156(1):56-64.
9. Moore KL, Persaud TVN: The developing human: Clinically oriented embryology, 5th Edn.; WB Saunders Philadelphia: 1993pp255-257.
10. Moses WR: Meckel's diverticulum: A report of two unusual cases. *New England Journal of Medicine*, 1947; 237:118-122.

11. Rabinwitz SS, Mills AK: Meckel's diverticulum. *e-medicine specialties* Pediatrics, General Medicine. *Article last updated-November; 17, 2008.*
12. Soltero MJ, Bill AH: The Natural history of Meckel's diverticulum and its relation to incidental removal. *American Journal of Surgery*, 1976;132(2):168-173.
13. Turgeon DK, Barnett JL: Meckel's diverticulum. *American Journal of Gastroenterology*, 1990;85:777-781.
14. Williams RS. Management of Meckel's diverticulum. *British Journal of Surgery*, 1981;68:477-480.